




Contents lists available at ScienceDirect

Taiwanese Journal of Obstetrics & Gynecology

journal homepage: www.tjog-online.com

Case Report

Molecular cytogenetic characterization of Jacobsen syndrome (11q23.3-q25 deletion) in a fetus associated with double outlet right ventricle, hypoplastic left heart syndrome and ductus venosus agenesis on prenatal ultrasound



Chih-Ping Chen^{a, b, c, d, e, f, *}, Liang-Kai Wang^a, Pei-Chen Wu^g, Tung-Yao Chang^g,
Schu-Rern Chern^b, Peih-Shan Wu^h, Yen-Ni Chen^a, Shin-Wen Chen^a, Chen-Chi Lee^a,
Chien-Wen Yang^b, Wayseen Wang^{b, i}

^a Department of Obstetrics and Gynecology, MacKay Memorial Hospital, Taipei, Taiwan

^b Department of Medical Research, MacKay Memorial Hospital, Taipei, Taiwan

^c Department of Biotechnology, Asia University, Taichung, Taiwan

^d School of Chinese Medicine, College of Chinese Medicine, China Medical University, Taichung, Taiwan

^e Institute of Clinical and Community Health Nursing, National Yang-Ming University, Taipei, Taiwan

^f Department of Obstetrics and Gynecology, School of Medicine, National Yang-Ming University, Taipei, Taiwan

^g Taiji Fetal Medicine Center, Taipei, Taiwan

^h Gene Biodesign Co. Ltd, Taipei, Taiwan

ⁱ Department of Bioengineering, Tatung University, Taipei, Taiwan

ARTICLE INFO

Article history:

Accepted 5 December 2016

Keywords:

chromosome 11q deletion
congenital heart defect
Jacobsen syndrome

ABSTRACT

Objective: We present molecular cytogenetic characterization of Jacobsen syndrome (11q23.3-q25 deletion) in a fetus associated with double outlet right ventricle (DORV), hypoplastic left heart syndrome (HLHS), and ductus venosus (DV) agenesis on prenatal ultrasound.

Case Report: A 26-year-old woman underwent prenatal ultrasound examination at 22 weeks of gestation, which revealed intrauterine growth restriction, short femurs, DORV, HLHS, DV agenesis, single umbilical artery, and curly fourth toe of the left foot. The parents elected to terminate the pregnancy, and a 500-g female fetus was delivered at 23 weeks of gestation with facial dysmorphism, bilateral campodactyly, and hammertoes. The parental karyotypes were normal. Cytogenetic analysis of the cord blood and umbilical cord revealed a karyotype of 46,XX,del(11)(q23). Array comparative genomic hybridization analysis of the DNA extracted from the umbilical cord revealed a 14.38-Mb deletion of 11q23.3-q25 encompassing *BSX*, *ETS1*, *FLI1*, and *ARHGAP32*. Metaphase fluorescence *in situ* hybridization analysis using the probes RP11-209L12 (11q25) and RP11-25M7 (11q11) showed a distal 11q deletion in the aberrant chromosome 11 in 17/17 cells examined.

Conclusion: Prenatal diagnosis of DORV, HLHS, DV agenesis associated with intrauterine growth restriction and short limbs should include a differential diagnosis of Jacobsen syndrome.

© 2017 Taiwan Association of Obstetrics & Gynecology. Publishing services by Elsevier B.V. This is an open access article under the CC BY-NC-ND license (<http://creativecommons.org/licenses/by-nc-nd/4.0/>).

Introduction

Jacobsen syndrome (JBS) or chromosome 11q deletion (11q23.3-q25) syndrome (OMIM 147791) is a contiguous gene deletion syndrome with a prevalence of 1/100,000 births, a female:male

ratio of 2:1, and a *de novo* occurrence in 85% of the reported cases [1]. JBS is associated with common features of intrauterine growth restriction (IUGR), postnatal growth retardation, psychomotor retardation, facial dysmorphism, abnormal platelet function, thrombocytopenia, pancytopenia, congenital malformations of the heart, kidney, gastrointestinal tract, genitalia, central nervous system and skeleton, and less common features of eyes, hearing, immune system, and endocrine problems [1].

Recently, Favier et al [2] proposed a genotype-phenotype correlation between the critical genes of *ETS1*, *FLI1*, *BSX*, and

* Corresponding author. Department of Obstetrics and Gynecology, MacKay Memorial Hospital, 92, Section 2, Chung-Shan North Road, Taipei 10449, Taiwan.
E-mail address: cpc_mmh@yahoo.com (C.-P. Chen).

ARHGAP32, and congenital heart defects (CHDs) and immunodeficiency; Paris-Trousseau syndrome (PTS) of thrombocytopenia and platelet dysfunction; intellectual disability; and autism spectrum disorder (ASD), respectively, in JBS.

Here, we present molecular cytogenetic characterization of 11q23.3-q25 deletion associated with double outlet right ventricle (DORV), hypoplastic left heart syndrome (HLHS), and ductus venosus (DV) agenesis on prenatal ultrasound in a fetus with JBS.

Case Report

A 26-year-old, gravida 2, para 1 woman was referred for genetic counseling at 23 weeks of gestation because of abnormal ultrasound findings of the fetus. Her husband was 31 years old. She and her husband and their 1-year-old daughter were healthy, and there was no family history of CHDs. Prenatal ultrasound examination at 22 weeks of gestation revealed IUGR, short femurs, single umbilical artery, DORV, HLHS, DV agenesis, and curly fourth toe of the left foot. The parents elected to terminate the pregnancy and accepted the suggestion of postnatal genetic investigation of the congenital malformations in the fetus. A 500-g female fetus was delivered at 23 weeks of gestation with hypertelorism, short nose, small low-set ears, hammertoes, and bilateral camptodactyly. The parental karyotypes were normal. Cytogenetic analysis of the cord blood and umbilical cord revealed a karyotype of 46,XX,del(11)(q23) (Figure 1). Array comparative genomic hybridization analysis of the DNA extracted from the umbilical cord by CytoScan 750K Array (Affymetrix, CA, USA) revealed a 14.38-Mb deletion of 11q23.3-q25 or arr 11q23.3q25 (120,553,181-134,937,416) \times 1.4 encompassing 70 OMIM genes including *BSX*, *ETS1*, *FLI1*, and *ARHGAP32* (Figure 2). Metaphase fluorescence *in situ* hybridization analysis using the bacterial artificial chromosome probes RP11-209L12 (11q25) and RP11-25M7 (11q11) showed a distal 11q deletion in the aberrant chromosome 11 in 17/17 cells examined (Figure 3).

Discussion

The present case prenatally manifested DORV, HLHS, DV agenesis, IUGR, short limbs, and hammertoes. Distal 11q deletion has been reported to be associated with prenatal ultrasound findings of increased nuchal thickness, trigonocephaly, facial dysmorphism, pyelectasis, a duplex renal system, orofacial cleft, HLHS, diaphragmatic hernia, agenesis of cerebellar vermis, omphalocele, and short femurs or limbs [3,4]. The present case had a 14.38-Mb deletion of 11q23.3-q25 encompassing *BSX*, *ETS1*, *FLI1*, and *ARHGAP32*.

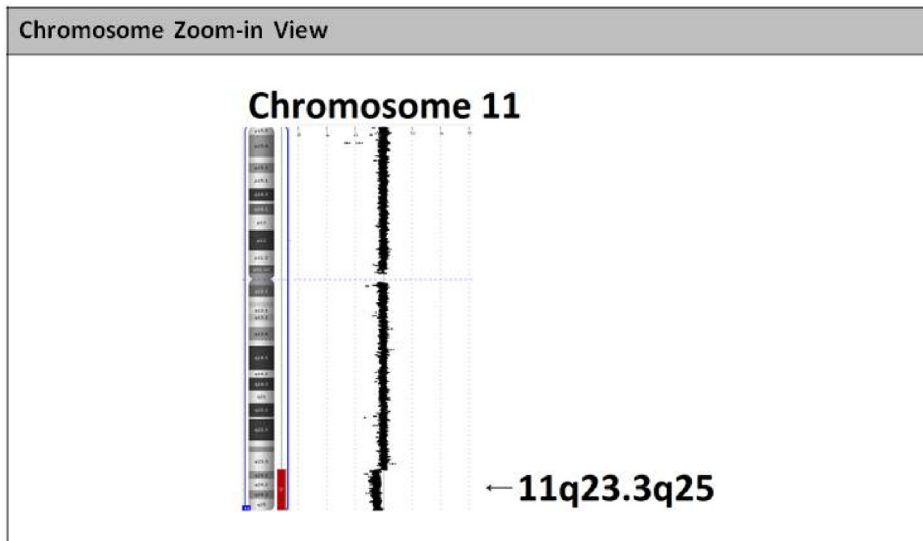
In a study of 110 cases with JBS, Grossfeld et al [5] found 56% (52/93) of the patients had serious CHD, and in the patients with CHD, two out of three had ventricular septal defect or a left-side obstructive lesion including HLHS, Shone's complex, coarctation, bicuspid aortic valve, aortic valve stenosis, mitral valve stenosis, and one out of three had miscellaneous lesions such as atrial septal defect, DORV, aberrant right subclavian artery, atrioventricular septal canal defect, d-transposition of the great arteries, dextrocardia, left-sided superior vena cava, tricuspid atresia, type B interruption of the aortic arch/truncus arteriosus, and pulmonary stenosis. Grossfeld et al [5] also found that HLHS occurred in 5–10% of all patients with JBS, which is significantly higher than the occurrence in any other chromosomal disorders.

ETS1 (OMIM 164720) is located at 11q24.3 and encodes v-ETS avian erythroblastosis virus E26 oncogene homolog 1 that belongs to ETS transcription factors which are involved in cellular growth, differentiation, hematopoiesis, lymphocyte development, vascular development, angiogenesis, and vascular inflammation and remodeling [6,7]. Ye et al [8] demonstrated that *ETS1* is expressed in the endocardium and neural crest during early mouse heart development, and gene-targeted deletion of *ETS1* in mice caused ventricular septal defect and HLHS, and suggested that *ETS1* is the critical gene responsible for CHD in JBS. Glessner et al [9] identified a *de novo* *ETS1* frameshift mutation (chr11: 128350159GTCCT>G, c.1046_1049delAGGA, [p.K349fs]) in a patient with JBS, HLHS, and mitral valve atresia, and suggested that *ETS1* mutations contribute

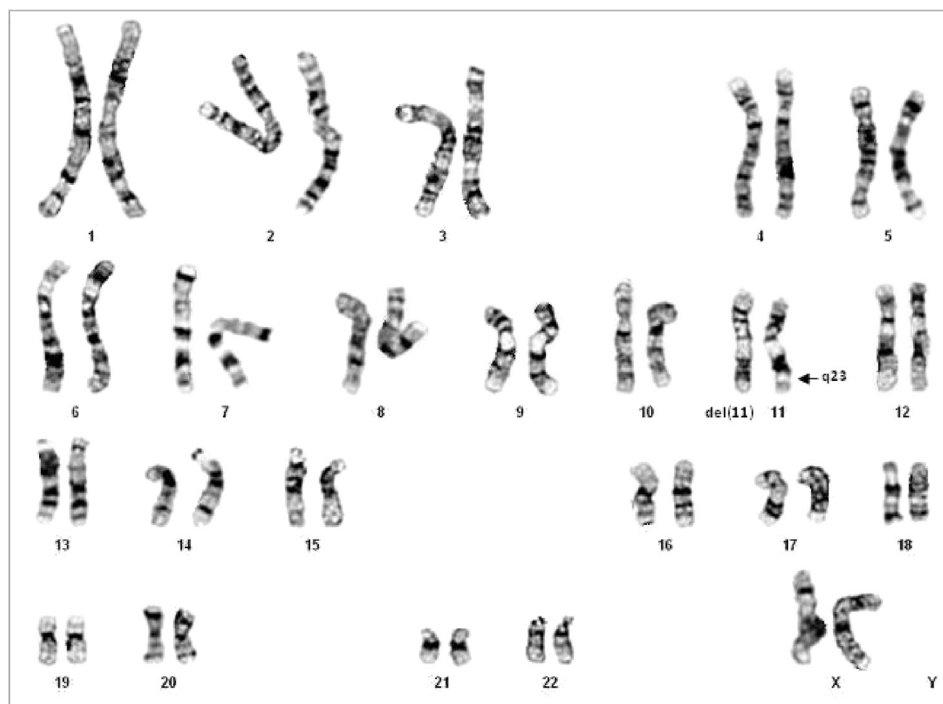

Figure 1. A karyotype of 46,XX,der(11)(q23). The arrow indicates the breakpoint of 11q23.

(A)



(B)

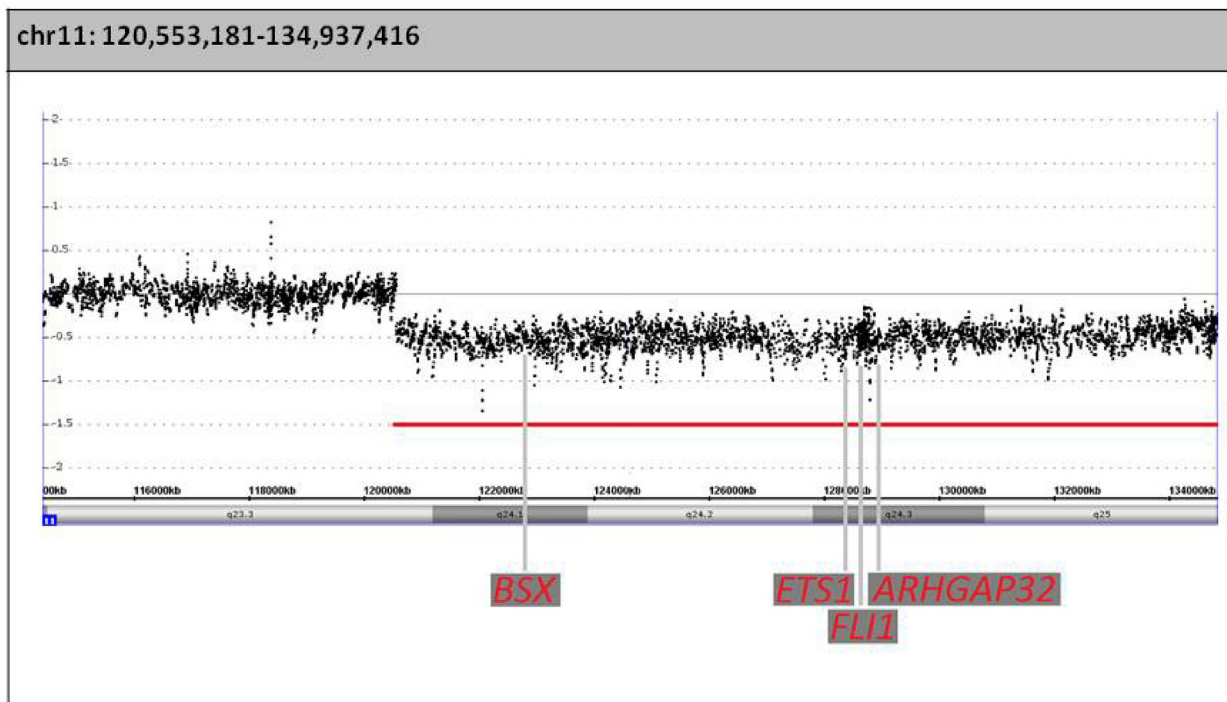


Figure 2. Array comparative genomic hybridization analysis shows a 14.38-Mb deletion of 11q23.3–q25, encompassing *BSX*, *ETS1*, *FLI1*, and *ARHGAP32*. (A) Chromosome zoom-in view and (B) chromosome 11.

to CHD in JBS. Nie and Bronner [10] using *Xenopus* embryos as a model system found that knockdown of *Ets1* in the mesoderm and neural crest causes an HLHS-like phenotype, and suggested that *Ets1* is required in both the cardiac neural crest and heart mesoderm, and is critical for normal heart development.

JBS has been reported to be associated with syndromic immunodeficiency. Haploinsufficiency of *ETS1* is speculated to be responsible for immunodeficiency in JBS [2,11,12] because *ETS1* plays a critical role of lymphocyte development [13–20].

FLI1 (OMIM 193067) is located at 11q24.3 and encodes friend leukemia virus integration 1 (FLI1) which plays an essential role in embryogenesis, vascular development, and megakaryopoiesis [21].

Grossfeld et al [5] reported that 94% (64/68) of the patients with JBS had thrombocytopenia and platelet dysfunction, also known as PTS. Thrombocytopenia, Paris-Trousseau type or TCPT (OMIM 188025) is a contiguous gene deletion syndrome associated with chromosome 11q23 deletion syndrome, thrombocytopenia, and platelet dysfunction [22,23]. Heterozygous loss of *FLI1* is associated with dysmegakaryopoiesis and the PTS in JBS [21].

BSX (OMIM 611074) is located at 11q24 and encodes brain-specific homeobox (*BSX*) which is a DNA-binding protein and a transcriptional activator and is expressed in hypothalamus [24–26]. *ARHGAP32* (OMIM 608541) is located at 11q24.3 and encodes RICS which is a neuron-associated GTPase-activating protein

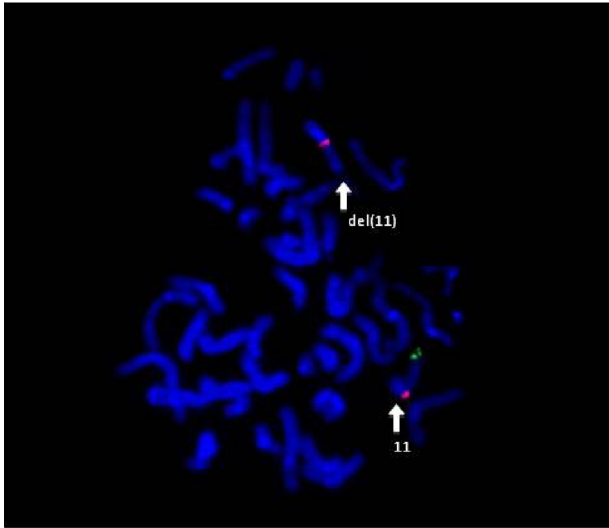


Figure 3. Metaphase fluorescence *in situ* hybridization analysis using the bacterial artificial chromosome probes RP11-209L12 (11q25; 134,774,408–134,930,933; fluorescein isothiocyanate, spectrum green) and RP11-25M7 (11q11; 55,251,029–55,415,907; Texas Red, spectrum red) shows one red signal and one green signal in the normal chromosome 11 and only one red signal in the aberrant chromosome del(11). del = deletion.

that regulates dendritic spine morphology and strength by modulating Rho GTPase [27]. Akshoomoff et al [28] found 47% (8/17) of the JBS patients had ASD and suggested that *ARHGAP32* is a critical gene responsible for ASD in JBS. Nakamura et al [29] found PX-RICS-deficient mice manifested behavior mimicking ASD in JBS through impaired GABAA receptor trafficking, and suggested that PX-RICS deletion is associated with ASD in JBS patients. In neurocognitive assessments in 13 patients with JBS, Grossfeld et al [5] found that 38% (5/13) had moderate mental retardation, 46% (6/13) had mild mental retardation, and 15% (2/13) were normal. Coldren et al [30] in a chromosomal microarray mapping of 14 patients with JBS suggested that *BSX* plays a role in neurocognitive and behavioral defects in JBS. Favier et al [2] suggested that *BSX* is a critical gene associated with recognition dysfunction in JBS patients.

In summary, we present molecular cytogenetic characterization of JBS (11q23.3–q25 deletion) in a fetus with IUGR, short femurs, DORV, HLHS, DV agenesis, single umbilical artery, and hammertoes on prenatal ultrasound. Prenatal diagnosis of DORV, HLHS, DV agenesis associated with IUGR, and short limbs should include a differential diagnosis of JBS.

Conflicts of interest

The authors have no conflicts of interest relevant to this article.

Acknowledgments

This work was supported by research grants MOST-104-2314-B-195-009 and MOST-105-2314-B-195-012 from the Ministry of Science and Technology and MMH-E-105-04 from MacKay Memorial Hospital, Taipei, Taiwan.

References

- [1] Mattina T, Perrotta CS, Grossfeld P. Jacobsen syndrome. *Orphanet J Rare Dis* 2009;4:9.
- [2] Favier R, Akshoomoff N, Mattson S, Grossfeld P. Jacobsen syndrome: advances in our knowledge of phenotype and genotype. *Am J Med Genet C Semin Med Genet* 2015;169C:239–50.
- [3] Chen C-P, Chern S-R, Tzen C-Y, Lee M-S, Pan C-W, Chang T-Y, et al. Prenatal diagnosis of de novo distal 11q deletion associated with sonographic findings

- of unilateral duplex renal system, pyelectasis and orofacial cleft. *Prenat Diagn* 2001;21:317–20.
- [4] Chen C-P, Chern S-R, Chang T-Y, Tzen C-Y, Lee C-C, Chen W-L, et al. Prenatal diagnosis of the distal 11q deletion and review of the literature. *Prenat Diagn* 2004;24:130–6.
- [5] Grossfeld PD, Mattina T, Lai Z, Favier R, Jones KL, Cotter F, et al. The 11q terminal deletion disorder: a prospective study of 110 cases. *Am J Med Genet* 2004;129A:51–61.
- [6] Sato Y. Role of ETS family transcription factors in vascular development and angiogenesis. *Cell Struct Funct* 2001;26:19–24.
- [7] Zhan Y, Brown C, Maynard E, Anshelevich A, Ni W, Ho IC, et al. Ets-1 is a critical regulator of Ang II-mediated vascular inflammation and remodeling. *J Clin Invest* 2005;115:2508–16.
- [8] Ye M, Coldren C, Liang X, Mattina T, Goldmuntz E, Benson DW, et al. Deletion of *ETS-1*, a gene in the Jacobsen syndrome critical region, causes ventricular septal defects and abnormal ventricular morphology in mice. *Hum Mol Genet* 2010;19:648–56.
- [9] Glessner JT, Bick AG, Ito K, Homsy JG, Rodriguez-Murillo L, Fromer M, et al. Increased frequency of *de novo* copy number variants in congenital heart disease by integrative analysis of single nucleotide polymorphism array and exome sequence data. *Circ Res* 2014;115:884–96.
- [10] Nie S, Bronner ME. Dual developmental role of transcriptional regulator *Ets1* in *Xenopus* cardiac neural crest vs. heart mesoderm. *Cardiovasc Res* 2015;106:67–75.
- [11] Seppänen M, Koillinen H, Mustjoki S, Tomi M, Sullivan KE. Terminal deletion of 11q with significant late-onset combined immune deficiency. *J Clin Immunol* 2014;34:114–8.
- [12] Dalm VASH, Driessen GJA, Barendregt BH, van Hagen PM, van der Burg M. The 11q terminal deletion disorder Jacobsen Syndrome is a syndromic primary immunodeficiency. *J Clin Immunol* 2015;35:761–8.
- [13] Bories J-C, Willerford DM, Grévin D, Davidson L, Camus A, Martin P, et al. Increased T-cell apoptosis and terminal B-cell differentiation induced by inactivation of the *Ets-1* proto-oncogene. *Nature* 1995;377:635–8.
- [14] Muthusamy N, Barton K, Leiden JM. Defective activation and survival of T cells lacking the *Ets-1* transcription factor. *Nature* 1995;377:639–42.
- [15] Barton K, Muthusamy N, Fischer C, Ting C-N, Walunas TL, Lanier LL, et al. The *Ets-1* transcription factor is required for the development of natural killer cells in mice. *Immunity* 1998;9:555–63.
- [16] Seidel JJ, Graves BJ. An ERK2 docking site in the Pointed domain distinguishes a subset of ETS transcription factors. *Genes Dev* 2002;16:127–37.
- [17] Eyquem S, Chemin K, Fasseu M, Bories J-C. The *Ets-1* transcription factor is required for complete pre-T cell receptor function and allelic exclusion at the T cell receptor beta locus. *Proc Natl Acad Sci USA* 2004;101:15712–7.
- [18] Foulds CE, Nelson ML, Blaszcak AG, Graves BJ. Ras/mitogen-activated protein kinase signaling activates *Ets-1* and *Ets-2* by CBP/p300 recruitment. *Mol Cell Biol* 2004;24:10954–64.
- [19] Wang D, John SA, Clements JL, Percy DH, Barton KP, Garrett-Sinha LA. *Ets-1* deficiency leads to altered B cell differentiation, hyperresponsiveness to TLR9 and autoimmune disease. *Int Immunol* 2005;17:1179–91.
- [20] Garrett-Sinha LA. Review of *Ets1* structure, function, and roles in immunity. *Cell Mol Life Sci* 2013;70:3375–90.
- [21] Hart A, Melet F, Grossfeld P, Chien K, Jones C, Tunnacliffe A, et al. *Fli-1* is required for murine vascular and megakaryocytic development and is hemizygously deleted in patients with thrombocytopenia. *Immunity* 2000;13:167–77.
- [22] Favier R, Douay L, Esteva B, Portnoi MF, Gaulard P, Lecompte T, et al. A novel genetic thrombocytopenia (Paris-Trousseau) associated with platelet inclusions, dysmegakaryopoiesis and chromosome deletion at 11q23. *C R Acad Sci III* 1993;316:608–701.
- [23] Favier R, Jondeau K, Boutard P, Grossfeld P, Reinert P, Jones C, et al. Paris-Trousseau syndrome: clinical, haematological, molecular data of ten new cases. *Thromb Haemost* 2003;90:893–7.
- [24] Cremona M, Colombo E, Andreatzoli M, Cossu G, Broccoli V. *Bsx*, an evolutionary conserved brain specific homeobox gene expressed in the septum, epiphysis, mammillary bodies and arcuate nucleus. *Gene Expr Patterns* 2004;4:47–51.
- [25] Chu H-Y, Ohtoshi A. Cloning and functional analysis of hypothalamic homeobox gene *Bsx1a* and its isoform, *Bsx1b*. *Mol Cell Biol* 2007;27:3743–9.
- [26] Sakkou M, Wiedmer P, Anlag K, Hamm A, Seuntjens E, Ettwiller L, et al. A role for brain-specific homeobox factor *Bsx* in the control of hyperphagia and locomotory behavior. *Cell Metab* 2007;5:450–63.
- [27] Okabe T, Nakamura T, Nishimura YN, Kohu K, Ohwada S, Morishita Y, et al. RICS, a novel GTPase-activating protein for Cdc42 and Rac1, is involved in the beta-catenin-N-cadherin and N-methyl-D-aspartate receptor signaling. *J Biol Chem* 2003;278:9920–7.
- [28] Akshoomoff N, Mattson SN, Grossfeld PD. Evidence for autism spectrum disorder in Jacobsen syndrome: identification of a candidate gene in distal 11q. *Genet Med* 2015;17:143–8.
- [29] Nakamura T, Arima-Yoshia F, Sakaue F, Nasu-Nishimura Y, Takeda Y, Matsuura K, et al. PX-RICS-deficient mice mimic Jacobsen syndrome-related autism spectrum disorder through impaired GABAA receptor trafficking. *Nat Commun* 2016;7:10861.
- [30] Coldren CD, Lai Z, Shragg P, Rossi E, Glidewell SC, Zuffardi O, et al. Comparative genomic hybridization mapping suggests a role for *BSX* and *Neurogranin* in neurocognitive and behavioral defects in the 11q terminal deletion disorder (Jacobsen syndrome). *Neurogenetics* 2009;10:89–95.